



Ameliorative Effect of Administering Avocado (*Persea americana*) Leaf Extract on Lead Acetate Toxicity in the Brain-cerebellum of Albino Rats

Ubi Essien Isaac^{1*}

¹Department of Anatomy and Forensic Anthropology, Faculty of Basic Medical Sciences,
Cross River University of Technology, Okuku Campus, Cross River State, Nigeria.

Author's contribution

The sole author designed, analysed, interpreted and prepared the manuscript.

Article Information

DOI: 10.9734/JOCAMR/2020/v10i430171

Editor(s):

(1) Dr. Francisco Cruz-Sosa Metropolitan Autonomous University Iztapalapa Campus, México.

Reviewers:

(1) Rudy Hartono, Makassar of Health Polytechnic, Indonesia.

(2) A. Vijaya Anand, Bharathiar University Coimbatore, India.

Complete Peer review History: <http://www.sdiarticle4.com/review-history/58817>

Received 02 May 2020

Accepted 08 July 2020

Published 23 September 2020

Original Research Article

ABSTRACT

Aim: To investigate whether the aqueous extract of avocado leaves can be used in alternative medicine for the remediation or treatment of lead poisoning in the brain.

Study Design: Pure Experiment, using animal models.

Place and Duration of Study: Department of Anatomy, College of Medicine and Health Sciences, Abia State University, Uturu, Nigeria; between January 2019 and June 2019.

Methodology: Twenty albino Wistar rats including both male and female, and weighing around 155 g were randomly assigned to four groups (designated as A,B,C and D), with each group consisting of five animals. While group A served as the control, group B was administered a daily dose of 500 mg/kg body weight of avocado leaf extract, group C received 150 mg/kg body weight per day of lead acetate, and group D was given 150 mg/kg body weight per day of lead acetate and immediately followed with 500 mg/kg body weight/day of the avocado leaf extract. Treatments were given once daily through the oral route using a syringe with attached micropipette tube for 15 days, while the animals had access to water and chow *ad libitum*. The rats were euthanized on the 16th day by cervical dislocation and the cranial cavity was carefully exposed in order to dissect the brain and to obtain tissue samples from the cerebellum, which were then prepared for microscopic examination using routine histological techniques, with hematoxylin and eosin (H&E) stains.

*Corresponding author: E-mail: isaacubireal@gmail.com;

Results: The findings showed the extract to be ameliorative by reducing histomorphological distortions of lead acetate toxicity in the brain, and thus caused moderate regeneration of the cerebellar tissue.

Conclusion: The outcome of this research therefore indicates that the avocado leaf extract has medicinal potentials and could serve as an herbal remedy in the alternative treatment of lead poisoning.

Keywords: Avocado; *Persea americana*; leaf extract; ameliorative effect; lead-acetate; toxicity; brain-cerebellum.

1. INTRODUCTION

Lead toxicity constitutes a serious public health challenge with the potential to produce adverse biological effects and thus interfere with a number of body functions. Lead otherwise known as plumbum (Pb) is a chemical element in the carbon group with atomic number 82 and considered a highly toxic metal that occurs naturally in the earth's crust [1][2]. Unique properties of lead such as softness or high malleability, ductility, melting point and resistance to corrosion have resulted in its widespread usage in different products and industries, which in turn leads to a manifold rise in the occurrence of free lead in biological systems and in all parts of the environment [2].

In humans, the routes of exposure include ingestion of lead- contaminated food or drinking water that contains lead leaching from older corroding pipes and fixtures, inhalation in industrial settings and dermal or skin contact. Lead pervades almost every organ and system in the human body, but the main target for lead toxicity is the central nervous system (CNS), both in adults and in children. It has been reported that lead-induced damage in parts of the brain like the cerebral cortex, hippocampus and cerebellum can lead to a variety of neurological disorders such as neurodegeneration, mental retardation, behavioral problems, nerve damage and possibly Alzheimer's disease, Parkinson's disease and schizophrenia [3].

Individual interventions have been suggested as one of the preliminary preventive measures towards lead toxicity [4]. Studies have shown that nutrition can play an important role in the prevention of lead-induced toxicity, as the uptake of certain antioxidant nutrients like mineral elements, flavonoids and vitamins are said to provide protection against lead poisoning [5]. Administration of various antioxidants can prevent or subdue various toxic effects of lead and generation of oxidative stress in particular

[6]. Chelation therapy has so far been used as the mainstay of treatment for lead toxicity. However, prevention is regarded as the best approach and this involves incorporation of various natural and synthetic antioxidants [7].

On the other hand, the avocado, scientifically known as *Persea americana* is a tree classified as a member of the flowering plant family *Lauraceae*. It is a medium to large tree, 9 to 20 meters tall and characterized as an evergreen plant whose leaves are usually 7 to 41 cm in length and can be elliptic, oval or lanceolate in shape; although some varieties lose their leaves for a short time before flowering [8]. Avocado leaf extract is said to contain phytochemical substances such as flavonoids, saponins, tannins and steroids with a strong antioxidant that can be used to prevent and cope with oxidative stress [9]. Avocados are commercially valuable and are cultivated in tropical and Mediterranean climates throughout the world. The fruit of this plant also called avocado pear or alligator pear in English is botanically a large berry containing a single large seed and surrounded by a buttery pulp. It has a green-skinned, fleshy body that may be pear-shaped, egg-shaped, or spherical [10][11][12]. Avocado is also known by a variety of names in different parts of the world. These include "avocado-brine" in German; "avocatier" or "Zaboka" in French; and "pagua" or "aguacate" in Spanish.

Avocado leaves have been reported to be a pharmaceutical ingredient widely used in extracts for therapeutic purposes and also as teas in folk medicine probably due to the diuretic properties [13][14]. The anti-oxidative and enzyme inhibition properties of the leaf and seed of *P. americana* could be part of the mechanism for their use in folklore medicine in the management and treatment of hypertension [15]. More so, previous studies have reported on the anti-cancerous activity of the extracts of leaves and fresh shoots of avocado, and an oral infusion of the leaves has been used to treat dysentery [8].



Fig. 1. Avocado tree with its leaves and fruits

Over the past decades, herbal medicine has become a thing of global importance with medicinal and economic implications [16]. However, the wide spread use of herbs throughout the globe has raised serious concerns over their quality, safety and efficacy. Thus, scientific assessment has become a precondition for the acceptance of herbal health claims, while there is an increasing interest worldwide in herbal medicine accompanied by laboratory investigations into the pharmacological properties of the bioactive ingredient and their ability to treat various diseases [17][18]. Furthermore, numerous drugs have entered the international market through exploration of ethnopharmacology and traditional medicine [19]. Hence, people who are thinking about using herbal medicine should first get information on it from reliable sources.

2. MATERIALS AND METHODS

2.1 Collection and Identification of Plant Material

Fresh leaves were collected from an avocado tree planted in the researcher's home town of Ugep in Cross River State, Nigeria, and thereafter taken for authentication at the botanical unit of Abia State University.

2.2 Preparation of Extract

The harvested avocado leaves were air-dried at room temperature for 10 days, pulverized using a laboratory blender, and the ground substance obtained was stored for further use. 50 g of the powdered sample/substance was extracted with

500 mls of distilled water (via maceration) for 48 hours. The mixture was decanted, filtered using sterile Whatman paper and evaporated to dryness to obtain an aqueous residue [20]. The semisolid extract obtained was preserved in a refrigerator for further use, and a stock solution was prepared by dissolving 10 g of the sample in 50 mls of water.

2.3 Acute Toxicity Studies of Avocado Leaf Extract

Based on previous information that avocado exhibits low toxicity, the limit test was carried out using the acute toxic class method 423 contained in the modified guidelines of Organization for Economic Cooperation and development (OECD) [21]. Thus, 12 healthy female rats underwent fasting overnight and they were divided into four groups (n=3). Group 1 received vehicle (distilled water) to serve as the control, whereas groups 2, 3 and 4 received 2000 mg/kg body weight of the extract. After administration the rats were observed continuously every one hour for four days. Further observation was carried out every 24 hours for 15 days to identify any change such as tremors, convulsions, lethargy, coma or any lethality. After four hours observation, the rats were allowed access to feed and water; and the experiment was then repeated one week later with another set of animals.

2.4 Experimental Animals

Twenty albino Wistar rats of both male and female genders, weighing around 155 g were procured and kept/secured in the animal house of the Department of Anatomy in the College of Medicine and Health Science of Abia State University. The animals were randomly distributed into cages and allowed to acclimatize for seven days in a well ventilated room with normal natural lighting condition, and as well given free access to standard rat chow (produced by Topfeeds Ltd) and distilled water *ad libitum*. Experimental procedures involving the use of animals and their care were employed in line with the existing guidelines.

2.5 Tools/ Equipment

These included rat cages, hand gloves, permanent marker, electronic weighing balance for measuring the test samples (Brand: M/s Vijay Scales & Sons, Guwahati, Kamrup, Assam), syringes for measuring the doses (BD Emerald 2ml syringe with 22Gx1), medical dissecting kit,

chemical reagents such as formalin (for fixation of tissue specimens), alcohol (for dehydration), xylene (for clearing or removal of alcohol), hematoxylin and eosin (for staining of tissues), specimen collection containers, pulverizer for grinding materials, graduated cylinder used to measure the volume of liquids (Brand: Nalgene), paraffin wax for embedding tissue, embedding mould for making blocks, rotary microtome for cutting thin sections of tissue, water bath used for relaxing and smoothening out of tissue prior to mounting on a glass slide, microscope slides used for holding the objects (i.e., tissue sections) for examination under a microscope, and a light microscope for viewing thin slices of tissue (Brand: MT5 Histology Pathology Lab Microscope).

2.6 Procurement and Preparation of Lead Acetate

50 g of lead acetate was procured from a chemical shop and a stock solution was prepared from it by dissolving 10 g in 60 mls of distilled water to yield a concentration of 0.17 g/ml.

2.7 Administration of Treatment

Twenty albino rats were divided into four groups designated as A, B, C, and D. Group A served as the control and received distilled water; group B was administered a dose of 500 mg/kg body weight per day of avocado leaf extract; group C was given 150 mg/kg body weight per day of lead acetate; and group D received 150 mg/kg b.w. of lead acetate and immediately followed with 500 mg/kg b.w. per day of avocado leaf extract. Treatments were given once daily via the oral route using a syringe with attached micropipette tube for 15 days. The rats were euthanized by cervical dislocation method [22], twenty-four hours post administration and the cranial cavity was carefully exposed in order to collect tissue samples from the cerebellum, which were then fixed in 10% formal saline in preparation for routine histological processing.

2.8 Histological Procedures

The tissue samples were preserved in 10% formal saline in a container with light-fitting lids for 3 days in order to prevent autolysis, improve staining quality and to aid optical differentiation of cells, and thereafter dehydrated in different grades of alcohol before clearing in xylene. This was followed by infiltration with molten paraffin wax to remove the clearing agent and then embedding in paraffin wax. The tissue was

mounted on wooden blocks to enable sectioning with a rotary microtome. The cut sections at 5 micron meters (μm) were floated in a warm water bath in order to enable mounting on microscope slides, and thereafter stained with hematoxylin and eosin dyes, while DPX (Distyrene Plasticizer Xylene) was promptly added to preserve the stain. The tissue slides were then allowed to dry for micrographing and interpretation [23].

3. RESULTS

3.1 Acute Toxicity Studies of Extract

Administration of aqueous leaf extract of *P. americana* (avocado) on albino Wistar rats did not show any toxic effect. More so, neither lethality nor toxic reaction was observed at a selected dose of 2000 mg/kg throughout the period of the toxicity studies. There was no record of mortality when the extract was used to treat the rats.

3.2 Physical Observation

In the course of animal treatment, the rats in group C (administered lead acetate) showed signs of irritability and became somewhat aggressive while handling. Also, there was a sudden appearance of an inflammation over the philtrum (medial cleft) of one of the animals in group D (administered lead acetate + *P. americana*) immediately treatment started. However, some healing was observed two days later and the recovery became rapid when some amount of the extract of avocado leaves was applied topically on the wound, which completely healed after six days. Neither lethality nor mortality was observed/recorded throughout the period of administering the test substances.

3.3 Histomorphological/Microstructural Results

The following micrographic plates are the outcome of studies of cerebellar tissue samples:

4. DISCUSSION

The result of the acute toxicity test of avocado (*Persea americana*) leaf extract did not show any toxic effects, and no toxic reaction, lethality or mortality was observed or recorded at the experimented dose of 2000 mg/kg body weight. This is in agreement with a previous report that *P. americana* leaf extract is well tolerated in general at a unique dose of 2000 mg/kg [24].

From the result of the physical observation, the rats in group C which received lead acetate were reported to show signs of irritability and became somewhat aggressive while handling. Irritability, fatigue and loss of appetite have been reported as some of the signs of repeated lead exposure [25]. The anti-inflammatory (or wound-healing) activity of the leaf extract of avocado in one of the animals in group D (administered lead acetate plus avocado extract) is in agreement with earlier findings [26]. More so, a similar report posits that complete healing (full epithelization) was observed in the excision wound model in rats which received oral and topical treatment of *P. americana* extract [27].

The cerebellum, also known as the small brain consists of an outer layer of highly convulated grey matter (cerebellar cortex) surrounding a highly branched body of white matter know as arbor vitae [28]. It is a vital component of the brain due to its role in the regulation of movement and control of balance. It coordinates gait and maintains posture, controls muscle tone and voluntary muscle activity. The gray matter of the cerebellar cortex divides into three layers: an external molecular layer, a middle Purkinje cell layer and an internal granular layer. Damage to the cerebellum often results in a loss of ability to control fine movements, maintain posture and motor learning. [29][30].

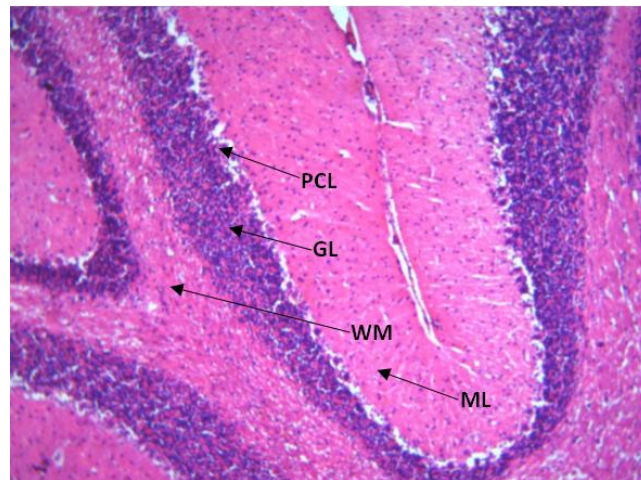


Fig. 2. Photomicrograph of Group A, control section of cerebellum, (x100)(H/E), shows normal architecture with molecular layer (ML), granular layer (GL), Purkinje cell layer (PCL) and white matter (WM)

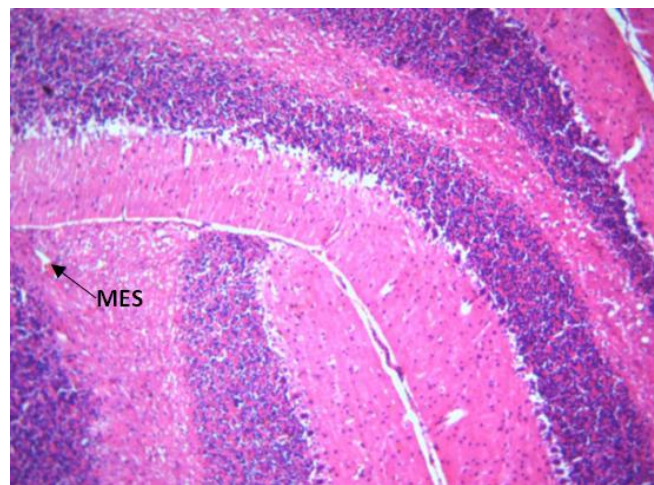


Fig. 3. Photomicrograph of group B, section of the cerebellum administered avocado (*P. americana*) leaf extract only, (x400) (H&E), shows mild eosinophilic substance (MES) with non significant changes in morphology when compared with the control

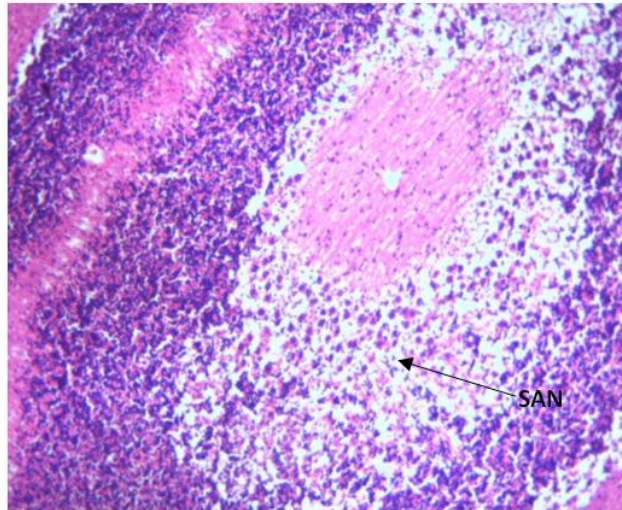


Fig. 4. Photomicrograph of group C, section of the cerebellum administered lead acetate only, (x100) (H&E), shows severe area of necrosis (SAN) and degeneration of the granular layer, with significant changes in morphology when compared with the control

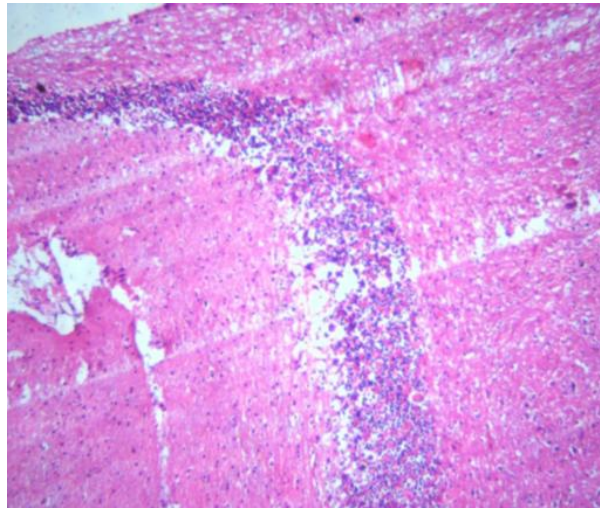


Fig. 5. Photomicrograph of group D, section of the cerebellum administered lead acetate and immediately followed with avocado leaf extract (x100) (H/E), shows moderate amelioration/regeneration when compared with group C that received lead acetate only

The photomicrograph of group A, being control section of the cerebellum as presented in Fig. 2 showed normal architecture with the presence of the three layers already mentioned as components of the gray matter, and of white matter surrounding the cerebellar cortex. Similarly, the administration of avocado leaf extract on albino rats in group B, did not cause any significant changes in the morphology as there was only some mild eosinophilic substance observed in the tissue when compared with the control group. The consumption of plant

products as complimentary/alternative medicine has been encouraged because they are relatively cheap. This is coupled with the belief that they could significantly contribute to the improvement of health in terms of cure and prevention of various human disorders [31]. In addition there are less frequent side effects reported when compared to modern medicine [32].

The administration of lead acetate on albino rats caused significant changes in the microstructure of the cerebellum. The Photomicrograph from

this section (Fig. 4) revealed poorly perfused neural tissue with severe area of necrosis within the gray matter, consistent with severely degenerated brain tissue. This finding conforms with those of earlier studies that had indicated that lead is a toxicant that induces damage in parts of the brain like the cerebral cortex, hippocampus and cerebellum, which can lead to a variety of neurological disorders [3][7]. The exposure to lead or its compounds produces various deleterious effects on the hematopoietic, renal, reproductive and central nervous systems [7]. Moreover, lead poisoning has been reported to cause loss of myelin sheath, reduction in the number of neurons, interference with neurotransmission and decrease in neuronal growth [33].

The histological section from group D representing a sample of the cerebellum of rats administered with lead acetate and immediately followed with avocado leaf extract (Fig. 5) showed moderate regeneration of the tissue when compared with the sample from group C (Fig. 4, that received only lead acetate). Previous studies have shown that the uptake of certain nutrients or anti-oxidant containing substances can provide protection against lead poisoning [5][6]. Avocado leaves are a pharmaceutical ingredient widely used for therapeutic purposes probably due to their medicinal properties [13][14]. The extract of leaves and fresh shoots of avocado exhibits anti-cancerous activity, and an oral infusion of the leaves has been used to treat dysentery [8]. Furthermore, a study on the inhibitory effect of aqueous leaf and seed extracts of *P. americana* (avocado) on angiotensin 1- converting enzyme, reports that the anti-oxidative and enzyme inhibition properties of the leaf and seed could be part of the mechanism for their use in folklore medicine in the management of hypertension [15].

The aqueous leaf extract of avocado possesses considerable protective effect against lead acetate toxicity in the cerebellum of rats. The mechanism of this neuroprotection could involve the exertion or influence of the antioxidant capacity on neural substrates, while its beneficial effect may be attributed to the phytochemical substances contained in it. Furthermore, the said leaf extract consisting of alkaloids, flavonoids, saponins and tannins was reported to produce dose dependent anti-ulcerative effect when administered orally to sick rats pre-treated with ulcerogenic drugs - indomethacin and ethanol [34]. Phytochemicals such as isorhamnetin,

luteolin, rutin, quercetin and apigenin have been isolated from avocado leaves, which help prevent the progress of various diseases related to oxidative stress [35]. Moreover, the leaves of avocado are said to have high antioxidant properties, total phenol and flavonoid content, which is a possible mechanism for their use in folklore medicine [15].

5. CONCLUSION

While lead has proved to be a toxicant that adversely affects the brain, the findings of this study has also indicated that the aqueous leaf extract of avocado has ameliorative potentials against lead-acetate toxicity, and may therefore be used as an herbal remedy in the alternative treatment/management of lead poisoning.

CONSENT

It is not applicable.

ETHICAL APPROVAL

Approval to conduct this research was granted by the research ethics committee of the Faculty of Basic Medical Science, Abia State University, Uturu, Nigeria, while the guidelines for the use of experimental animals were followed.

COMPETING INTERESTS

Author has declared that no competing interests exist.

REFERENCES

1. Mason LH, Harp JP, Han DR. Pb neurotoxicity: Neuropsychological effects of lead toxicity. Biomed Res Int. 2014;4: 812. Available:<http://ax.doi.org/10.1155/2014/840547> [Accessed 2019 March 12].
2. Agency for Toxic Substances and Disease Registry. Lead (Pb) Toxicity: What are the physiologic effects of lead exposure? 2019. Available:<https://www.atsdr.cdc.gov/csem/csem.asp?csem=34&po=10> [Last accessed 2019 March 3].
3. Saunders T, Liu Y, Buchner V, Tchounwou PB. Neurotoxic effects and biomarkers of lead exposure: A review. Rev Environ Health. 2009;24:15-45.

4. Guidotti TL, Ragain L. Protecting children from toxic exposure: three strategies. *Pediatr Clin North Am.* 2007;54(3):227-37. DOI: 10.1016/j.pcl.2007.02.002
5. Hsu PC, Guo YL. Antioxidant nutrients ad lead toxicity. *Toxicology.* 2002;180(1):33-44. DOI: 10.1016/s0300-483x(02)00380-3
6. Antonio Garcia MT, Masso-Gonzalez EL. Toxic effects of perinatal lead exposure on the brain of rats: Involvement of oxidative stress and the beneficial role of antioxidants. *Food Chem Toxicol.* 2008; 46(6):2089-95. DOI: 10.1016/j.fct.2008.01.053
7. Flora G, Grupta D, Tiwari A. Toxicity of lead: A review with recent updates. *Interdiscip Toxicol.* 2012;5:47-58.
8. Orwa C, Mutua A, Kindt R, Jamandas R, Anthony S. *Agroforestry Database: A tree reference and selection guide version 4.0; 2009.* Available: <https://www.worldagroforestry.org/sites/treedbs/treedatabaseses.asp> [Accessed 2019 April 22].
9. Rahman N, Dewi NU, Bohari. Phytochemical and antioxidant activity of avocado leaf extract (*Persea americana* Mill.) *Asian J Sci Res.* 2018;11(3):357-63. DOI: 10.3923/ajsr.2018.357.363
10. Morton JF. Avocado; In: *Fruits of warm climates.* Centre for new crops and plant products, Department of Horticulture and landscape Architecture, Purdue University, West Lafayette, IN. 1987;91-102.
11. Chen H, Morrell PL, Ashworth V, de la Cruz m, Clegg MT. Tracing the geographic origins of major avocado cultivars. *J Herid.* 2008;100(1):56-65. DOI: 10.1093/jheredesn068
12. Storey WB. What kind of fruit is the avocado? *California Avocado Society.* 1973-74;57:70-1.
13. Vendruscolo GS, Mentz LA. Ethnobotanical survey of the medicinal plants used by the community of Ponta Grossa neighborhood, porto Alegre, Rio Grande do Sul, Brazil. *Iheringa serie Botanica.* 2006;61:83-103. DOI: 10.1590/51516-05722012000200010
14. Wright CI, Van-Bruen I, Kroner CI, Koning MM. Herbal medicines as diuretics: A review of the scientific evidence. *J Ethnopharmacol.* 2007;114(1):1-31.
15. Odubanjo VO, Oboh G, Makinde OA. Inhibitory effects of aqueous extracts of avocado pear (*Persea americana*) leaf and seed on angiotensin 1 – converting enzyme: A possible means in treating/managing hypertension. *J Applied Life Sci Int.* 2016;4(1):1-9. DOI: 10.9734/JALS1/2016/21605
16. Yasir M, Das S, Kharya MD. The phytochemical and pharmacological profile of *persea Americana* Mill. *Pharmacogn Rev.* 2010;4(7):77-84. DOI: 10.4103/0973-7847.65332
PMCID: PMC3249906. PMID: 22228945
17. Ekor M. The growing use of herbal medicines: Issues relating to adverse reactions and challenges in monitoring safety. *Front Pharmacol.* 2014;4:177-82. DOI: 10.3389/fphar.2013.00177
PMCID: PMC3887317. PMID: 24454289
18. Cooper EL. Complementary and alternative medicine, when rigorous can be science. *Evid Based Complement Alter Med.* 2004;1:1-4.
19. Patwardhan B, Warude D, Pushpangadan P, Bhatt N. Ayurveda and traditional Chinese medicine: A comparative overview. *Evid Based Complement Alternat Med.* 2005;2(4):465-73. DOI: 10.1093/ecam/neh140
PMCID: PMC1297513. PMID: 16322803
20. Azwanida NN. A review on the extraction methods use in medicinal plants, principle strength and limitation. *Med Aromat plants.* 2014;4(3):196-201. DOI: 10.4172/2167-0412.1000196
21. Organization for Economic Cooperation and Development (OECD). *Guidance Document on Acute Oral Toxicity.* Environmental Health and Safety Monograph Series on Testing and Assessment. 2000;24.
22. The University of Texas at Austin. *Guidelines for the Use of Cervical Dislocation for Rodent Euthanasia.* Institutional Animal Care and Use Committee. 2013;004. Available: <https://www.avma.org/issues/animalwelfare/euthanasia.pdf> [Accessed 2019 January 15]
23. Slaoui M, Fiette L. Histopathology procedures: from tissue sampling to histopathological evaluation. *Methods Mol Biol.* 2011;601:69-82. DOI: 10.1007/978-1-60761-849-2_4
24. Kamagate M, Kouame NM, Koffi E, Kadja AB, Camilla K, Yao NA, et al. Acute toxicity and hypoglycemic activity of the leaf extracts of *Persea americana* mill. (lauraceae) in wistar rats.

- Afr J Pharm Pharmacol. 2016;10(33):690-8.
25. Murrel D. Lead poisoning. Cafasso J. (Ed.); 2018.
Available:<https://www.health/lead-poisoning> [Last accessed 2019, April 15].
26. Lotito S, Frei B. Conception of flavonoid – rich foods and increased plasma antioxidant capacity in humans: Cause, consequence, or epiphenomenon? Free Radic Biol Med. 2006;41(12):1727-46.
Doi:10.1016/j.freeradbiomed.2006.04.033
27. Nayak BS, Raju SS, Chalapathi Rao CV. Wound healing activity of *Persea americana* (avocado) fruit: A preclinical study on rats. J Wound Care. 2008;17(3): 123-6.
DOI: 10.12968/jowc.2008.17.3.28670
28. Roostaei T, Nazeri A, Sahraian MA, Minagar A. The human cerebellum: A review of physiologic neuroanatomy. Neurol Clin. 2014;32(4):859-69.
DOI: 10.1016/j.ncl.2014.07.013
29. Van-Essen DC, Donahue CJ, Glasser MF. Development and evolution of cerebral and cerebellar cortex. Brain Behav Evol. 2018; 91(3):158-69.
30. Hawkes R. The Ferdinando Rossi Memorial Lecture: Zones and stripes – pattern formation in the cerebellum. Cerebellum. 2018;17(1):12-6.
31. Bandaranayake WM. Quality control, screening, toxicity, and regulation of herbal drugs; in Modern Phytomedicine: Turning Medicinal Plants into Drugs. Ahmad I, Aqil F, Owais M. (eds). Weinheim: Wiley-VCH GmbH & Co. KGaA. 2006;25-57.
DOI: 10.1002/9783527609987.ch2
32. Hu H, Shih R, Rothenberg S, Schwartz BS. The epidemiology of lead toxicology in adult: Measuring dose and consideration of other methodologic issues. Environ Health Perspect. 2007;115(3):455-62.
DOI: 10.1289/ehp.9783
PMCID:PMC1849 918
33. Pearson HA, Schonfeld DJ. Lead; In Rudolph's Pediatrics. Rudolph CD. (Ed.). 21st ed. Philadelphia, McGraw Hill Professional. 2003;28-34.
34. Ukwe CV, Nwafor SV. Anti-ulcer activity of aqueous leaf extract of *Persea americana* (family-lauraceae). Nig J Pharm Res. 2004;3:91-5.
DOI: 10.4314/njpr.v3i1.35390
35. Owolabi MA, Coker HAB, Jaja SI. Bioactivity of the phytoconstituents of the leaves of *persea Americana*. J Med Plant Res. 2010;4(12): 1130-5.
DOI: 10.5897/JMPR09.429

© 2020 Isaac; This is an Open Access article distributed under the terms of the Creative Commons Attribution License (<http://creativecommons.org/licenses/by/4.0>), which permits unrestricted use, distribution, and reproduction in any medium, provided the original work is properly cited.

Peer-review history:
The peer review history for this paper can be accessed here:
<http://www.sdiarticle4.com/review-history/58817>